



Maurice Adatto, MD
Medical Director
Skinpulse Dermatology & Laser Center
Geneva, Switzerland

Cynergy with MultiPlex, an Effective Method of Treating Leg Veins

Background

Aesthetic practitioners are often asked to remove leg veins. They have used a pulsed dye laser (PDL) for small leg veins^{1,2} or the Nd:YAG laser alone to reach the deep, large veins of the face and legs.^{3,4} The 1064-nm Nd:YAG laser device has a greater depth of penetration, but is also associated with significant adverse effects (i.e. scarring, blistering, erythema, edema) because fluences ranging from 120 to 600 J/cm² are required to achieve 75% or greater improvement in deep vessels (Table 1).

MultiPlex™ Technology

Available only in the Cynergy™ laser (Cynosure, Inc.), MultiPlex™ technology combines PDL with a high-powered 1064-nm Nd:YAG laser. The MultiPlex feature allows practitioners to treat vascular lesions with two different wavelengths delivered sequentially from the same handpiece with a selectable delay between the two pulses. The PDL energy first converts hemoglobin to methemoglobin and micro-clots which, in turn, absorb more 1064-nm energy than hemoglobin. This conversion allows practitioners to use lower Nd:YAG fluences, reducing scarring, pitting, and other adverse effects while improving outcomes. The delay between the two pulses is set based on the flow rate of the vessel. The delay allows the converted methemoglobin to flow within the structure while being contained in the area of treatment.

Methods

A healthy 40-year-old woman presented with a desire to remove the large blue reticular veins from the posterior side of both legs (Figures 1a and 2a) for cosmetic reasons. The patient agreed to be treated with the Cynergy with MultiPlex system at 7 mm spot size (PDL: 6.5 J/cm², 20 ms; Nd:YAG: 40 J/cm², 30 ms; delay: long). The patient received a single 15-minute treatment with a 3-month follow-up visit.

Table 1. Studies using PDL or Nd:YAG laser devices for the treatment of vascular lesions.

Reference (No. of Patients)	Areas Treated (Vessel Diameter)	PDL Fluence (J/cm ²) (No. of Tx)	Nd:YAG Fluence (J/cm ²) (No. of Tx)	Efficacy	Adverse Effects	Follow-Up (Mo.)
West et al ¹ (n=20)	Face, leg telangiectasia (<1 mm)	15-20 (1-2)	—	75%-94% improvement after 2 Tx;	Pain, hyperpigmentation, hypopigmentation	3
Tanghetti et al ² (n=40)	Face, leg telangiectasia;	14-16 (1-2)	—	At least 75% clearance of 70%-80% vessels (1 tx)	Purpura, hyperpigmentation	12
Sadick ³ (n=10)	Leg; red and blue vessels (<3 mm)	—	250-600 (1-3)	50%-75% improvement (3 mo, 20% of patients); >75% improvement (6 mo, 80% of patients)	Moderate discomfort during tx; Hyperpigmentation, focal blistering and crusting, telangiectasia matting	6
Mordon et al ⁴ (n=11)	Thigh, legs, knee, ankle (1-2 mm)	—	300-360 (1-3)	55% clearance (1 tx), 85% clearance (2 tx)	Moderate pain, erythema, edema, hyperpigmentation, matting	1.5

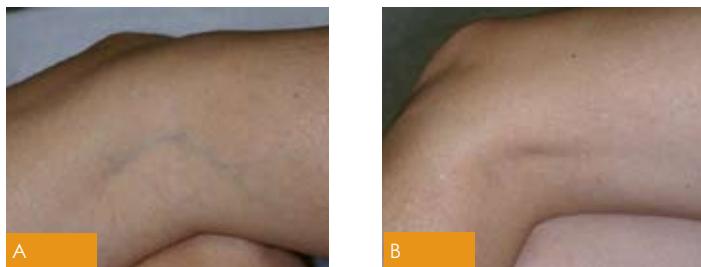


Figure 1. A 40-year old woman with large reticular veins on the left leg (a) and three months after a single treatment with the Cynergy with MultiPlex system (b) at 7 mm spot size (PDL: 6.5 J/cm², 20 ms; Nd:YAG: 40 J/cm², 30 ms; delay: long). Adverse effects were limited to mild, temporary erythema and purpura.

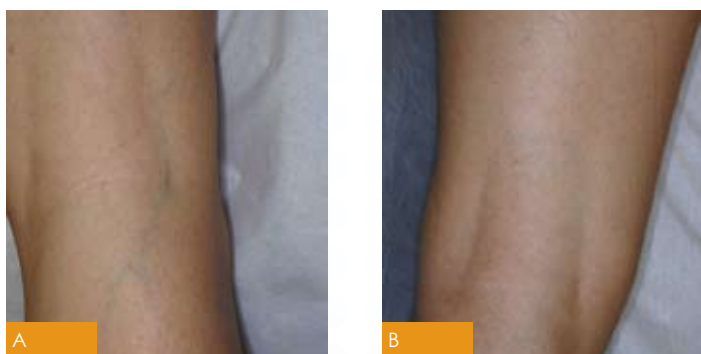

Figure 2. A 40-year old woman with large reticular veins on the right leg (a) and three months after a single treatment with the Cynergy with MultiPlex system (b) at 7 mm spot size (PDL: 6.5 J/cm², 20 ms; Nd:YAG: 40 J/cm², 30 ms; delay: long). Adverse effects were limited to mild, temporary erythema and purpura.

Legs were treated to the appearance of transient blanching of the vessels and without anesthesia, pretreatment care, or posttreatment care. The SmartCool was set at fan speed 5 during all treatments.

Results and Discussion

The results of the present study confirm those of earlier studies^{5,6} because in this patient, only a single MultiPlex treatment session was required to remove large reticular veins from both legs. The patient reported mild erythema that disappeared three days after treatment and transient purpura in one small area. The results three months after treatment are shown in Figures 1b and 2b.

The advantage of dual sequential wavelength treatment is that lower fluences of the Nd:YAG laser are required to produce favorable outcomes, thus reducing edema and other adverse effects that typically accompany the 44 to 49 J/cm² and 50 to 65 J/cm², much lower than the 120 to 600 J/cm² fluences of earlier studies.^{3,4,7} The Nd:YAG fluences used in the present study (40 J/cm²) were even lower.

Conclusions

The dual sequential wavelength Cynergy with MultiPlex appears to provide quick, efficient removal of large reticular leg veins with only mild, temporary erythema and purpura.

Bibliography

1. West TB, Alster TS. Comparison of the long-pulse dye (590-595 nm) and KTP (532 nm) lasers in the treatment of facial and leg telangiectasias. *Dermatol Surg* 1998;24:221-226.
2. Tanghetti E, Sherr EA. Treatment of telangiectasia using the multi-pass technique with the extended pulse width, pulsed dye laser (Cynosure V-Star). *J Cosmet Laser Ther* 2003;5:71-75.
3. Sadick NS. Laser treatment with a 1064-nm laser for lower extremity class I-III veins employing variable spots and pulse width parameters. *Dermatol Surg* 2003;29:916-919.
4. Mordon S, Brisot D, Fournier N. Using a "non uniform pulse sequence" can improve selective coagulation with a Nd:YAG laser (1.06 μm) thanks to Met-hemoglobin absorption: a clinical study on blue leg veins. *Lasers Surg Med* 2003;32(2):160-170.
5. Tanghetti E. Multiplex 595, 1064 nm laser treatment for blebbed port wine birthmarks and telangiectasia. Paper presented at: Annual Meeting of the American Society of Laser Medicine and Surgery; April 5-9, 2006; Boston, Mass.
6. Adrian R. Multiplex Treatment of Leg Veins: How I Do It [white paper]. Westford, Mass.: Cynosure, Inc.; 2006.
7. Sarradet DM, Hussain M, Goldberg DJ. Millisecond 1064-nm neodymium: YAG laser treatment of facial telangiectases. *Dermatol Surg* 2003;29:56-58.